


Contents lists available at Sjournals



Journal homepage: [www.Sjournals.com](http://www.Sjournals.com)



### Case report

## Intestinal cestodes of poultry *Raillietina echinobothrida* and *Choanotaenia Infundibulum* infection in a commercial Japanese quail (*Coturnix coturnix japonica*) farm in Apomu, Osun State, Nigeria

O.W. Gamra<sup>a</sup>, R.E. Antia<sup>b</sup>, O.O. Falohun<sup>c,\*</sup>

<sup>a</sup>National Veterinary Research Institute, Vom, Plateau State, Nigeria.

<sup>b</sup>Department of Veterinary Pathology, University of Ibadan, Nigeria.

<sup>c</sup>Department of Veterinary Microbiology and Parasitology, University of Ibadan, Nigeria.

\*Corresponding author; Department of Veterinary Microbiology and Parasitology, University of Ibadan, Nigeria.

### ARTICLE INFO

#### Article history,

Received 16 March 2015

Accepted 17 April 2015

Available online 28 April 2015

#### Keywords,

*Raillietina echinobothrida*

*Choanotaenia infundibulum*

Histology

Japanese quail

Nigeria

### ABSTRACT

*Raillietina echinobothrida* and *Choanotaenia infundibulum* are important species of cosmopolitan cestodes of poultry occurring in the small intestine and transmitted by ants, houseflies and beetles. Ten moribund and fifteen carcasses of Japanese quail birds (*Coturnix coturnix japonica*) with heavy intestinal tapeworm infection were brought to the post-mortem section of the department of Veterinary Pathology, University of Ibadan. The farmer reported that there was sporadic mortality (11.2%) on his farm as he has lost almost 112 birds of a total flock size of 1000 capacity within the space of two weeks as an average of 8 mortalities were recorded per day prior to the time of presentation. Postmortem examination revealed severe emaciation of the breast muscles and protrusion of the keel bone, as intestinal lumen of all the carcasses was severely filled with whitish worms measuring about 15cm-25cm in length as their anterior ends were firmly attached to the intestinal mucosal and dark red exudates (digested blood) was seen. Histopathology reveals transverse section of worms associated with sloughing off, necrosis and degeneration of intestinal villi. The worms were confirmed to be *Choanotaenia infundibulum* and *Raillietina echinobothrida*. This is the first recorded case of *Choanotaenia infundibulum* and *Raillietina echinobothrida* infection in Japanese quail (*Coturnix japonica*) in Nigeria. This report

may be an alert of the possibility of on-going pathogenicity of these poultry cestodes in quails in Nigeria. We strongly encourage quail farmers to frequently change the birds' bedding and always keep it dry which can help to avoid infections because it shortens the survival of the gravid segments and the eggs. Also farmers should put up measures to avoid contamination of feed with ants, houseflies and beetles, and also prevent access of these intermediate hosts to birds as chemical control of flies, ants and termites in poultry houses is essential for the prevention of these pathogenic helminth infections. However, for both economic and ecologic reasons, outdoor use of insecticides should not be a routine practice.

© 2015 Sjournals. All rights reserved.

---

## 1. Introduction

The scientific designation for Japanese quail is *Coturnix japonica* (Mizutani, 2003), this bird has great economic importance as it produces eggs and meat which are enjoyed for their unique flavour (Kayang et al., 2004), its cost of maintenance being relatively low, associated with its small body size (80-300g) and coupled with its short generation interval (3-4 generations per year). The resistance of these birds to diseases and high egg production rendered it an excellent laboratory animal (Baumgartner, 1994; Oguz and Minvielle, 2001). Many species of tape worms (e.g. *Choanotaenia infundibulum*) are now recorded in intensive poultry breeding farms because the birds come in contact with the intermediate hosts of these cestodes majorly beetles, houseflies and ants in deep litters inhabiting poultry farms (Reid and McDougald, 1997). Avian cestodiasis constitutes one of the most common endoparasitism causing serious troubles in poultry production, it does not only cause loss of body weight of the birds, but also may cause several problems in affected flocks such as enteritis, anaemia due to blood loss, low production, nervous manifestations and death (Calneck et al., 1997). *Raillietina echinobothrida* is the most important species in terms of prevalence and pathogenicity in poultry production (Permin and Hansen, 2003). The tape worm inhabits the small intestine and it's responsible for stunted growth of young birds, emaciation of adult and decreased egg production in laying birds. Severe intestinal lesions and diarrhoea could arise, which ostensibly results in ill health and death (Lalchandama, 2009). Under heavy infestation, *R. echinobothrida* is listed as one of the most pathogenic tape-worms, causing intestinal nodules which often result in degeneration and necrosis of intestinal villi (McDougald, 2003).

## 2. Case report

Ten moribund and fifteen carcasses of Japanese quail birds (*Coturnix coturnix japonica*) were brought to the post-mortem section of the department of Veterinary Pathology, University of Ibadan from Anuoluwapo Commercial quail farm located in Apomu, Osun state, Nigeria. The farmer reported that there was sporadic mortality (11.2%) on her farm as she has lost almost 112 birds from a total flock size of 1000 capacity within the space of two weeks with an average of 8 mortalities recorded per day prior to the time of presentation. The birds were sourced from National Veterinary Research Institute, Ikire, Osun state at day old and were vaccinated against Newcastle Disease (ND) at 6 weeks old. They were raised on dip litter system till 12 months old when this current episode of mortality set in. The birds showed similar clinical signs at 6 months old and a few mortalities were recorded. The birds were given antibiotics (Enrofloxacin) but the outcome was not significant. Clinical signs reported include dullness, unthriftiness, emaciation, weakness, bloody diarrhea, reduced growth, uneven body weight and decreased egg production.

## 3. Collection of tapeworms

Live adult cestodes were collected upon autopsy from the small intestines of the Japanese quails, the tape worms were washed in 9% phosphate buffered saline (PBS) and then transferred to the Veterinary Parasitology laboratory section of the Department of Veterinary Microbiology and Parasitology, University of Ibadan for parasitological identification under light microscope as described by Roy et al., (2007).

#### 4. Histological sectioning of the intestinal mucosal

Sections of the intestines were cut and fixed in 10% buffered formol saline which was then taken to the Veterinary pathology laboratory for histopathology. The intestinal segments were processed, dehydrated in increasing concentrations of ethanol, cleared in xylene and embedded in paraffin. The paraffin blocks were sectioned with a microtome at 5µm thickness, and placed on slides which were stained by the Harris haematoxylin and eosin method (Bancroft and Gamble, 2002).

### 5. Results

#### 5.1. Gross pathology

The post mortem examination of both sacrificed and dead quails revealed that all the carcasses had ruffled feathers and were moderately to severely emaciated. Seven out of 14 birds examined showed severe emaciation of the breast muscles with protrusion of the keel bone (fig 1). The intestinal lumen (duodenum and jejunum) of all the carcasses when cut open were severely filled with whitish worms measuring about 15cm to 25cm in length as their anterior ends were firmly attached to the intestinal mucosal and dark red exudates (digested blood) was seen. The duodenal mucosa was thickened and hyperaemic showing chronic catarrhal enteritis and haemorrhagic enteritis (fig 2a-b).

#### 5.2. Histology

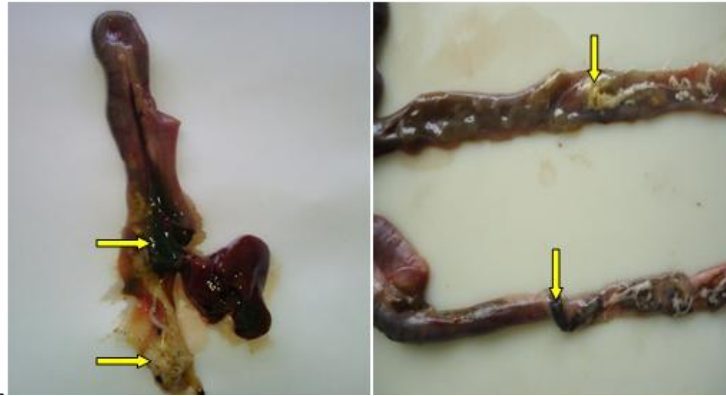Histopathology of the intestine of the quails reveals transverse section of *Raillietina echinobothrida* and *Choanotaenia infundibulum* forming a cup-shaped appearance associated with sloughing off, necrosis, partial atrophy and degeneration of villi and mucosal glands along with heterophilic infiltration (fig 3).

#### 5.3. Parasite identification

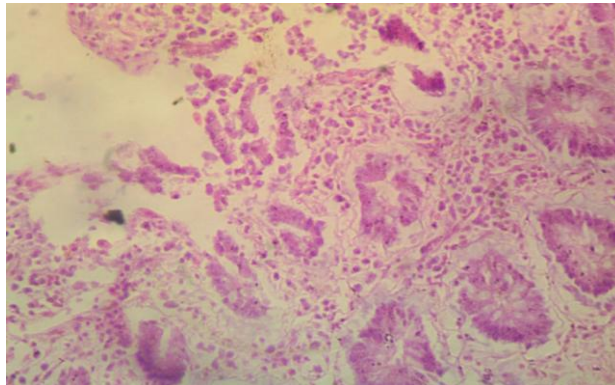
The tapeworms were identified microscopically as *Choanotaenia infundibulum* and *Raillietina echinobothrida*. The scolex of *Choanotaenia infundibulum* was identified to be triangular in shape and pointed anteriorly. The worms measured 10-15 cm long bearing rostellum hooks, the sucker is almost round in shape, the neck is narrow, short and followed by broad segments which gradually increased in length. The mature segments are more or less bell shaped, broader posteriorly than anteriorly with pointed posterior corners giving the worm serrated appearance (fig 4). The scolex of *Raillietina echinobothrida* is spherical in shape, the worms measured up to 25cm with short and broad neck, the rostellum is retractile and armed with hooks, the sucker is oval in shape also armed with hooks. (fig 5).



Fig. 1. Severe emaciation of the breast muscle with prominent keel bone in one of the infested Japanese quails.



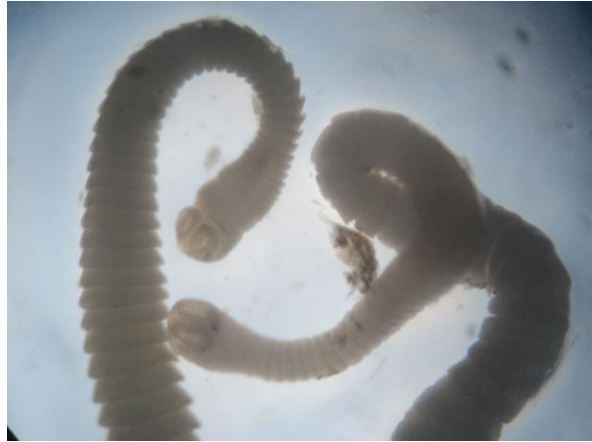**Fig. 2(a-b).** Intestinal lumen of affected Japanese quail (duodenum and jejunum) severely filled with tapeworms and dark red exudates (arrows). The duodenal mucosa is thickened and hyperaemic. The intestinal tract has been incised to expose the heavy load of the cestodes.



**Fig. 3.** Photomicrograph of the intestine from affected Japanese quail reveals villi and cryptal necrosis with inflammatory cellular infiltration.



**Fig. 4.** *Choanotaenia infundibulum* with triangular and anteriorly pointed scolex. Segments are wider posteriorly with pointed corners giving the worm a saw-edge appearance.



**Fig. 5.** *Raillietina echinobothrida* with the scolex spherical in shape, the worms measured up to 25cm with short and broad neck. The sucker is oval in shape and armed with hooks.

## 6. Discussion

Infection by cestodes in poultry is not a fulminating disease with high mortality, however, the harm done through an insidious and chronic process in birds' population as a whole brings about a massive and total loss (Salam et al., 2010). The morphological description of *Choanotaenia infundibulum* coincided with those mentioned by Soulsby, (1982) and Ahmed and Nabila, (2004). Meanwhile the morphological features and general measurements of *Raillietina echinobothrida* recorded in this case agrees with that reported by Azzazy, 1979; Soulsby, 1982, Mahdy and Olfat, 1988; Urqhart et al., 1996 and Ahmed and Nabila., 2004. The examined quail birds at postmortem revealed gross lesions in the form of emaciation indicated by prominent keel bone, chronic catarrhal enteritis, hemorrhagic enteritis, mucoid diarrhea and firm attachment of the cestodes to the intestinal mucosa, these findings have been previously reported to be consistent in cases of *Choanotaenia infundibulum* and *Raillietina echinobothrida* in birds by Calneck et al., 1997; Shahin et al., 2011 and Waghmare et al., 2014. The attachment of the parasites was observed in this study as the cause of traumatic lesions which might favour secondary bacterial infection and hence more severe cellular reactions at the site. The present study revealed histologically, sections of the parasites in the intestinal mucosa of the affected quails and also mucosal plugs were observed drawn inside the rostellum which formed a cup-shaped appearance as this is possibly due to the penetrative ability of these parasites in which they firmly attach their scolices thereby feeding and damaging the intestinal lining while lesions in the intestines were characterized by varying degrees of necrotic and degenerative changes due to sloughing of mucosa, partial villous atrophy with broadened surface and increased vascularity observed in the duodenum and jejunum in heavy and mixed infestations as this observation is similar with the report of Salam et al, (2010) and Premaalatha et al., 2014. This is the first recorded case of *Choanotaenia infundibulum* and *Raillietina echinobothrida* infection in Japanese quail (*Coturnix japonica*) in Nigeria, as this report may be an alert of the possibility of on-going pathogenicity of these poultry cestodes in quails in Nigeria. We strongly encourage quail farmers to frequently change the birds' bedding and always keep it dry which can help to avoid infections because it shortens the survival of the gravid segments and the eggs. Also farmers should put up measures to avoid contamination of feed with ants, houseflies and beetles, and also prevent access of these intermediate hosts to birds as chemical control of flies, ants and beetles in poultry houses is essential for the prevention of these pathogenic helminth infections. However, for both economic and ecologic reasons, outdoor use of insecticides against ants, beetles or flies should not be a routine practice. Flocks at risk can be treated with specific taenicides (niclosamide or praziquantel), as most of these active ingredients are available as additives for feed or drinking water, or as tablets for oral delivery.

## Competing interests

The authors declare that they have no competing interests.

## References

- Ahmed., Nabila, S.I., 2004. Some studies on parasitic helminthes infecting domestic chicken in Beni –Sueif Governorate. M.V.SC. Thesis; Faculty of Vet. Med.; Cairo University.
- Bancroft, J.D., Gamble, M., 2002. Theory and practice of histological techniques. 5th ed., Harcourt Publ. Ltd., London. 125-131.
- Baumgartner, J., 1994. Japanese quail production, breeding and genetics. World`s Poult. Sci. J. 50, 227-235.
- Calneck, B.W., Barnes, H.J., Beard, C.W., McDougald, L.R., Saif, Y.M., 1997. Diseases of Poultry 10th Ed. Editorial Board for the American Association of Avian Pathologists. Mosby – Wolfe.
- El - Azzazy, O.M., 1979. Studies on helminth parasites of poultry in Sharkia governorate. M.V.Sc. Thesis, Fac.Vet. Med. Zagazig University.
- Kayang, B., Vigna, B., Inove, A., Murayam, M., Miwa, M., Monvoisin, J.L., Ito, S., Minvielle, F., 2004. A first generation micro satellite linkage 35, 195-200.
- Lalchhandama, K., 2009. On the structure of *Raillietina echinobothrida*, the tapeworm of domestic fowl. Science Vision 9 (4), 174-182.
- Mahdy., Olfat, A., 1988. Studies on parasitic worms infesting chickens and ducks in Giza governorate, Egypt. M.V.Sc. Thesis, Fac. Vet. Med. Cairo University.
- McDougald, L.R., 2003. Cestodes and trematodes. In: Diseases of Poultry, 11th edn (Saif, Y.M., Barnes, H.J., Fadly, A.M., Glisson, J.R., McDougald, L.R., Swayne, D.E., eds). Iowa State Press, Blackwell Publishing Company, Iowa, USA, 961-972.
- Mizutani, M., 2003. The Japanese quail, laboratory animal research station, Nippon institute for biological science, Kobuchizawa, Yamanashi, Japan, 408-0041.
- Oguz, I., Minvielle, F., 2001. Effect of genetics and breeding on carcass and meat quality of Japanese quail: A review. Proceedings of XV European symposium on the quality of poultry meat, WPSA Turkish branch, Fusadasi-Turkey, 9-12.
- Permin, A., Hansen, J.W., 2003. The epidemiology, diagnosis and control of poultry parasites: An FAO Handbook. Food. Agr. Organ. Unit. Nation. Rome, Italy, 6-8.
- Premalatha, B., Chandrawathani, P., Jamnah, O., Erwanas, A.I., Lily Rozita, M.H. Ramlan, M., 2014. Intestinal *Cestode Choanotaenia Infundibulum* in chicken. Malays. J. Vet. Res. 5(2), 73-75.
- Reid, W.M., McDougald, L.R., 1997. Cestodes and trematodes. In diseases of poultry, 10th edition, Iowa State University, 850-864.
- Roy, B., Lalchhandama, K., utta, B.K., 2007. Anticestodal efficacy of *Acacia oxyphylla* on *Raillietina echino*-bothrida: a light and electron microscopic studies. *Pharmacologyonline*, 1, 279-287.
- Salam, S.T., Mir, M.S., Khan, A.R., 2010. The prevalence and pathology of *Raillietina cesticillus* in indigenous chicken (*Gallus gallus domesticus*) in the temperate Himalayan region of Kashmir. Vet. Arhiv. 80, 323-328.
- Shahin, A.M., Lebdah, M.A., Abu-Elkheir, S.A., Elmeligy, M.M., 2011. Prevalence of chicken cestodiasis in Egypt. New. York. Sci. J. 4(9), 21-29.
- Soulsby, E.J.L., 1982. Helminths, Athropods and Protozoa of domesticated animals. Baillière Tindall, London, UK. 7th Edition. 809.
- Urquhart, G.M., Armour, J., Duncan, J.L., Dunn, A.M., Jennings, F.W., 1996. Veterinary Parasitology, 2nd ed. Blackwell Science Ltd . Osney Mead. Oxford Oel, London.
- Waghmare, S., Sherkhane, A.S., Chavan, R., Gomase, V., 2014. Redescription on *Raillietina echinobothrida* (Pasquale, 1890) (Cestoda: Davaineidae) and study of conserved domain across divergent phylogenetic lineages of class cestoda. J. Vet. Sci. Technol. 5(3), 187.